

Advanced Techniques in Hip Arthroscopy

*Christopher M. Larson, MD

*Carlos A. Guanche, MD

*Bryan T. Kelly, MD

*John C. Clohisy, MD

Anil S. Ranawat, MD

Abstract

The indications for hip arthroscopy are expanding as the understanding of hip disease increases. Improved instrumentation and technical skills also have facilitated the ability to treat some hip disorders arthroscopically. Femoroacetabular impingement (FAI) is increasingly recognized as a disorder that can lead to progressive intra-articular chondral and labral injury. Although FAI is usually treated through an open approach, limited-open and all-arthroscopic approaches have been described. Various arthroscopic techniques allow treatment of labral and acetabular rim pathology as well as peripheral compartment femoral head-neck abnormalities. Early outcomes of limited-open and all-arthroscopic treatment of FAI are only beginning to be reported but appear to compare favorably with those of open dislocation procedures. Although labral tears traditionally have been treated with simple débridement, concerns have been raised about the consequences of removing the labrum. Modified portal placement and hip-specific suture anchors are now being used in an effort to repair some labral tears. Snapping hip disorders typically are treated nonsurgically. For persistent symptoms, arthroscopic release is successful, compared with open release, and allows additional evaluation of the hip joint during surgery.

Diagnosis and management of traumatic and atraumatic hip instability continue to be challenging. Hip arthroscopy has been shown to be effective in the treatment of hip instability in some patients. The extra-articular peritrochanteric space is receiving increased attention. The arthroscopic anatomy has been well defined, but the treatment of greater trochanteric pain syndrome and arthroscopic repair of abductor tendon tears are only beginning to be reported. Improved techniques and longer-term outcomes studies will further define the optimal role of hip arthroscopy.

Instr Course Lect 2009;58:423-436.

*Christopher M. Larson, MD or the department with which he is affiliated has received research or institutional support from Zimmer, Biomet, Omeros Corporation, and Arthrex and is a consultant or an employee for Smith & Nephew. Carlos A. Guanche, MD or the department with which he is affiliated has received research or institutional support, miscellaneous nonincome support, commercially derived honoraria, or other nonresearch-related funding from Arthrex; holds stock or stock options in Arthrex; and is a consultant or an employee for Arthrex and Zimmer. Bryan T. Kelly, MD is a consultant for or an employee of Pivot Medical. John C. Clohisy, MD or the department with which he is affiliated has received research or institutional support from Zimmer and is a consultant or an employee for Zimmer.

Hip arthroscopy has received much attention in recent years. Although the procedure was initially used for diagnosis and treatment of a few conditions, including labral tears, unstable chondral flaps, and loose bodies, improved techniques and enhanced understanding of hip disease have increased the indications for hip arthroscopy. The indications, techniques, and early outcomes for conditions such as femoroacetabular impingement (FAI), labral tears, snapping hip disorders, traumatic and atraumatic hip instability, and peritrochanteric space pathology are discussed in this chapter.

Femoroacetabular Impingement

FAI is the result of abnormal contact between the proximal femur and the acetabular rim.¹⁻³ The abnormality can occur on the femoral or the acetabular side or both. The two primary mechanisms of FAI are pincer and cam impingement.

Pincer impingement results from contact between an abnormal acetabular rim and a normal femoral head-neck junction; cam

impingement is the result of contact between an abnormal femoral head-neck junction and a normal acetabulum. Pincer and cam impingement are discussed in detail in chapter 21.

Patients with FAI usually are in the second, third, or fourth decade of life. They typically describe groin pain or deep lateral pain exacerbated by strenuous activity. Pain often occurs with prolonged sitting and sometimes when the patient rises from a chair, moves in or out of a vehicle, or sits with the legs crossed in a figure-of-4 position. Except for pain while sitting, pain at rest is unusual early in the disease and in the absence of significant degenerative changes. Patients frequently report a diagnosis of low back disease, recurrent hip flexor strain, sports hernia, or a history of unsuccessful surgery unrelated to the hip joint.

The physical examination typically reveals limitations in hip flexion and internal rotation. A flexion, abduction, and external rotation test often reveals an increased distance from the examination table to the lateral aspect of the knee and elicits groin pain on the symptomatic side.⁴ With the patient supine, the anterior or posterior impingement test can elicit groin pain from anterolateral or posterolateral impingement, respectively.⁵ In the anterior impingement test, the hip is flexed at least 90°, with internal rotation and adduction. The posterior impingement test involves hip extension and external rotation.

Plain radiographs must be critically analyzed to identify the areas of impingement. Typically, the radiographs include an AP view with the coccyx centered over the pubic symphysis and with a 2- to 5-cm distance between the sacrococcygeal junction and the pubic symphysis.⁶ Local anterior overcoverage (retroversion) of

the acetabulum is indicated by a crossover sign and a posterior wall sign.⁷ Global acetabular overcoverage (coxa profunda) is present when the ilioischial line lies lateral to the floor of the acetabulum or tear-drop.⁸ A detailed discussion of the radiographic features of femoroacetabular impingement is presented in chapters 21 and 23. FAI is nonsurgically treated by avoiding of painful activities such as deep hip flexion, aggressive hip flexion-based weight training, and athletic activities that could cause pain. Although relatively pain-free core strengthening can be used for these patients, aggressive attempts at restoring hip flexion and internal rotation should be avoided because they typically lead to a worsening of symptoms. Unfortunately, patients often continue to have pain during activities of daily living or are unwilling to refrain from painful athletic endeavors.

Joint-preserving surgery is considered for patients with FAI who have minimal degenerative changes in the hip. The procedure involves correcting the underlying structural deformity. The associated labral and articular cartilage disease is treated by trimming prominent areas of acetabular overcoverage, with concomitant labral detachment and refixation or débridement, or recontouring aspherical areas of the femoral head-neck junction. The most well-established approach is through an open dislocation.^{1,2,9,10} Hip arthroscopy using a limited-open approach without dislocation and an all-arthroscopic approach have recently been described.^{4,11-20} The indications for open and arthroscopic treatment have not been well defined, and the decision should be based on the pattern of impingement and the experience of the surgeon.

One surgical strategy for treating FAI combines hip arthroscopy with a limited anterior approach to the hip.^{20,21} This technique is most suitable for focal cam impingement or localized pincer impingement with excessive anterolateral femoral head coverage. It is less suitable for a hip with a circumferential or complex impingement pattern that cannot be completely reached using an anterior approach. This procedure can be used by surgeons who are making a transition from an open dislocation approach to an all-arthroscopic approach.

The surgical procedure begins with hip arthroscopy to treat acetabular labral and articular cartilage pathology, as well as associated synovitis and any other intra-articular abnormalities. A limited anterior approach to the hip is then used to address structural impingement abnormalities. The incision should begin 1 cm inferior to the anterosuperior iliac spine and should extend 8 to 10 cm distally. The tensor fascia is incised over the muscle, the tensor fascia lata muscle is reflected laterally, and the sartorius is reflected medially. The rectus femoris tendon is identified, and it can be released to gain wide exposure of the anterior hip capsule. An I-shaped arthrotomy is made for joint access, and the capsular flaps are reflected medially and laterally. Using the more normal anteromedial head-neck junction as a guide, osteochondroplasty of the anterior, anterolateral, and lateral femoral head-neck junction is performed. Care is taken to avoid extending the osteochondroplasty too far posteriorly because the retinacular vessels run along the posterolateral aspect of the femoral neck.²² After the bone resection, improvement in the hip range of motion can be evaluated by direct

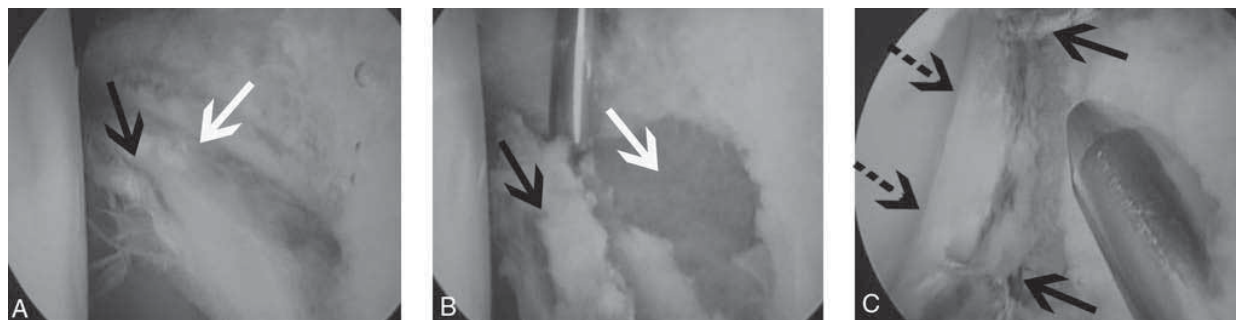


Figure 1 **A**, Arthroscopic view of the left hip of a 17-year-old soccer player, taken from the anteroparatrochanteric portal. The femoral head is to the left, and the acetabulum is to the right. The patient has peripheral labral ecchymosis consistent with pincer impingement (*white arrow*) and disruption of the labrochondral junction with early chondral delamination consistent with cam impingement (*black arrow*). **B**, The labrum (*black arrow*) after it was detached with a beaver blade from the acetabular rim through the area of undersurface tearing. Rim trimming to the acetabular rim (*white arrow*) was performed with an arthroscopic burr. **C**, The labrum after it was repaired and refixed to the acetabulum using two suture anchors (*solid arrows*) and traction was released. The normal sealing function of the labrum against the femoral head has been restored (*dashed arrows*).

observation, palpation, or fluoroscopy. If acetabular-side correction is needed, the hip can be distracted to improve access to the acetabular rim. The labrum can be repaired or further detached to allow osteoplasty of the acetabular rim followed by reattachment of the acetabular labrum. The anterior capsular flaps and rectus femoris tendon are then repaired.

All-arthroscopic approaches for treating FAI have been described^{4,11-20} and are associated with a steep learning curve for the surgeon. The procedure can be performed with the patient in the supine or lateral position after an intrasurgical “around the world” fluoroscopic evaluation is used to determine the extent of cam impingement.¹⁹ Several views are taken: AP, neutral and maximal internal-external hip rotation; frog-leg lateral, with 40° hip flexion and external rotation; and cross-table lateral, with 15° internal rotation. The anterolateral and anterior arthroscopic portals are typically used. The anterior portal is created 1 to 2 cm more distal than is customary

to allow better access to the acetabulum for rim trimming and labral re-fixation.

Any acetabular overcoverage is corrected first, with the extremity in traction. Intra-articular findings consistent with pincer impingement include extension of the periphery of the acetabulum well beyond the labrochondral junction and associated peripheral labral ecchymosis, labral flattening, labral maceration, or labral ossification. If pincer impingement and labral disease are present, an arthroscopic knife can be used to detach the labrum from the rim, beginning at the anterior portal and extending along the area of labral damage and acetabular chondrosis to create a bucket-handle tear. A 5.5-mm burr is used to trim the rim 5 to 10 mm (based on presurgically determined center-edge angles) to establish a center-edge angle of approximately 25° to 30°. To treat any posterior areas of acetabular impingement, a posterolateral portal can be created to allow predictable trimming of the posterior and inferior rims. Microfracture is performed if full-thickness acetabular

chondral defects are present after rim trimming. If necessary to refix the labrum, two to five suture anchors are typically placed just off the rim. A mattress suture technique can be used to preserve the labrum’s sealing function^{15,19} (Figure 1).

Cam impingement is treated through a capsulectomy or an extended capsulotomy from the anterior portal to the posterolateral portal.^{4,16,18} The anterolateral portion of the femoral head-neck junction is brought into view with hip flexion. Intrasurgical fluoroscopy can be judiciously used to verify the position and extent of the osteoplasty. A 5.5-mm burr is used beginning at the anteromedial femoral head-neck junction, which can be reached with flexion and external rotation. The osteoplasty is continued superior with hip internal rotation, and the lateral neck is further recontoured with increased hip flexion to avoid a cookie-bite appearance. Repeated external rotation is used to evaluate the amount of resection. Resection of more than 30% is rarely needed and should be avoided to prevent postsurgical femoral neck fracture.²³

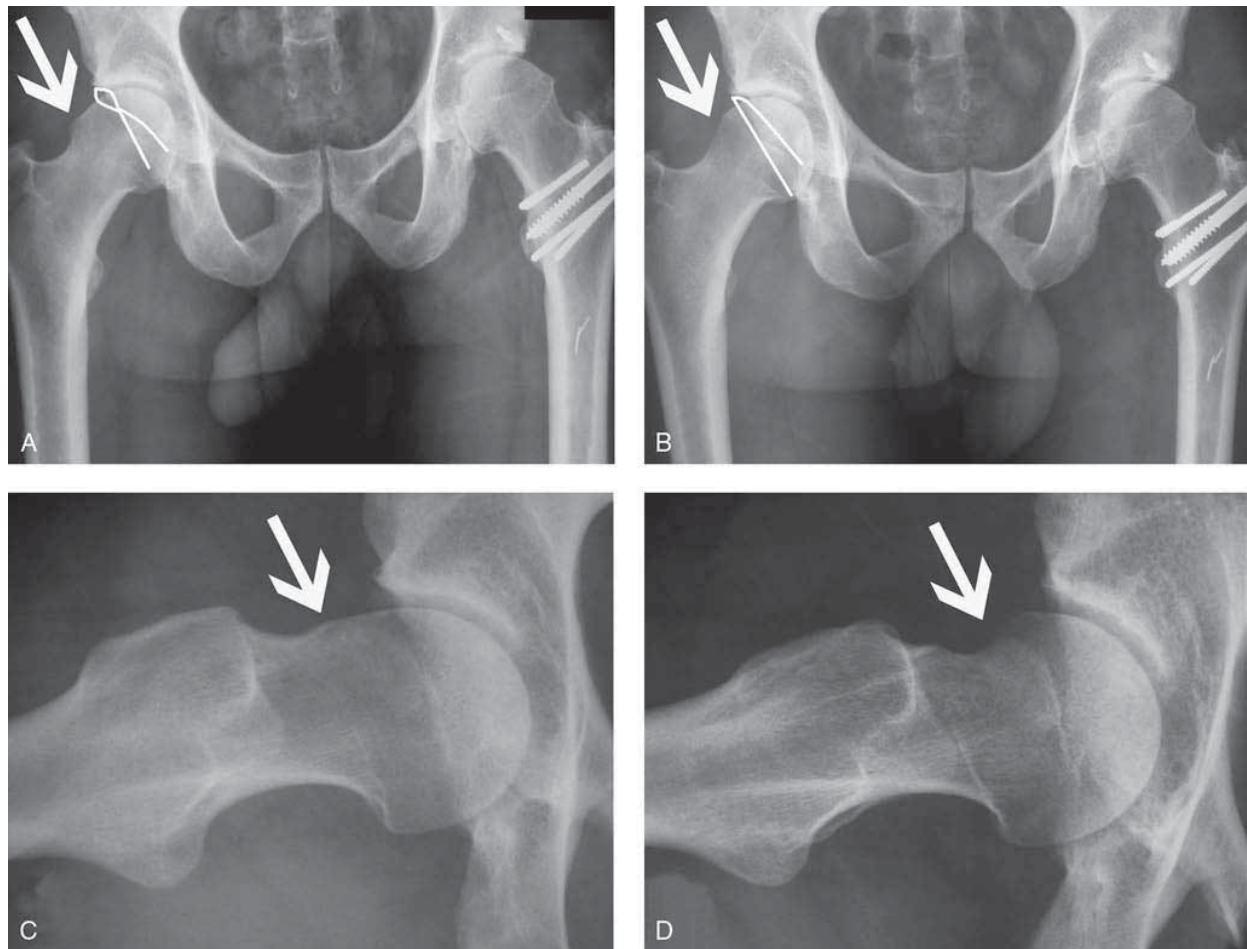


Figure 2 **A**, A presurgical AP radiograph showing a decreased femoral head-neck offset (*arrow*) and a positive crossover sign (*outline*) in the right hip, consistent with cam and pincer impingement, respectively. The patient had undergone an open procedure on the left hip that was complicated by postoperative trochanteric nonunion. **B**, A postoperative AP radiograph showing an improved femoral head-neck offset (*arrow*) and absence of the crossover sign (*outline*) after arthroscopic femoral osteochondroplasty and acetabular rim trimming. **C**, A presurgical frog-leg lateral radiograph consistent with cam impingement (*arrow*). **D**, A postoperative frog-leg lateral radiograph showing arthroscopic recontouring of the femoral head-neck junction (*arrow*).

Extension of the hip and maximal internal rotation can bring more superior areas of impingement into view. To preserve the retinacular vessels, care must be taken to avoid continuing the osteoplasty too far posterolateral on the superior femoral neck. The osteoplasty is continued until a normal head-neck offset can be seen on all “around the world” evaluation views. The adequacy of bony resection is confirmed by direct arthroscopic obser-

vation of an impingement-free range of hip motion through maximal flexion, adduction, abduction, and internal and external rotation (Figure 2).

Early outcomes of the arthroscopic and limited-open approach and the all-arthroscopic approach are being reported. At 1- to 3-year follow-up, both approaches appear to offer results comparable to those of open dislocation.^{19,21} Regardless of the surgical approach, long-term

pain relief or alteration in the natural progression of osteoarthritis require longer-term follow-up studies. (DVD 39.1)

Arthroscopy Combined With Proximal Femoral and Periacetabular Procedures

Hip arthroscopy can be used as an adjunct to reconstructive osteotomy. Although symptomatic structural deformities are commonly associated with intra-articular abnormali-

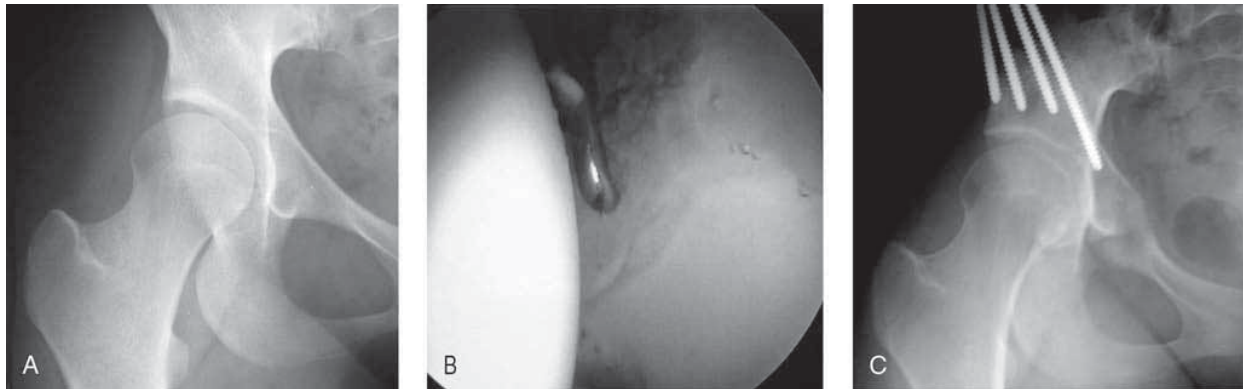


Figure 3 **A**, AP radiograph of the right hip in an 18-year-old woman with symptomatic acetabular dysplasia and intermittent mechanical symptoms of locking and catching. **B**, Hip arthroscopy reveals an intrasubstance unstable flap tear of the anterior acetabular labrum, which was treated with partial labral resection. **C**, A periacetabular osteotomy was performed to correct the structural deformity of the acetabulum. The patient had an excellent clinical result at 2-year follow-up.

ties, most osteotomies are extra-articular, and often they do not correct associated intra-articular abnormalities. A symptomatic acetabular labral tear or chondral flap in a patient with underlying developmental dysplasia of the hip is commonly treated with hip arthroscopy and combined osteotomy^{24,25} (Figure 3). Unstable intra-articular tissues are treated arthroscopically, and a periacetabular osteotomy is performed during the same surgery, with the patient supine.²⁶ Patients with major structural deformities and associated intra-articular disease have achieved encouraging symptom relief.²⁶

Labral Tears and Repair Techniques

The acetabular labrum is a triangular band of fibrocartilage attached to the base of the acetabular rim. The labrum provides structural resistance to lateral motion of the femoral head within the acetabulum, enhances joint stability, and preserves joint congruity.²⁷ Like the meniscus, it distributes synovial fluid and provides proprioceptive feedback.²⁸

Disruption of the labral structure alters the biomechanical properties of the joint. Whether labral tears lead to degenerative joint disease has yet to be determined. They also may contribute to the progression of osteoarthritis.^{29,30} Such findings have led to increased interest in labral repair indications and techniques.

The forces acting on a hip with a torn labrum often cause groin or deep lateral pain during sports activity. The symptoms also can include buckling, clicking, catching, and locking. The most commonly reported cause of a traumatic labral tear is an externally applied force to a hyperextended and externally rotated hip,³¹ although a specific inciting event often cannot be identified. Degenerative tears also can result from FAI, which typically overloads the anterosuperior labrum, leading to attritional tears.³

Lage and associates³² have described an arthroscopic classification of labral tears. Radial flap tears were found to be the most common type, followed by radial fibrillated, longitudinal peripheral, and excessively mobile tears. Degenerative tears

were classified based on their location and extent, which are correlated with the extent of degenerative and erosive change.³³ These articular lesions are most often located at the labrochondral junction.^{29,30}

Labral tears caused by trauma usually are isolated in one quadrant based on the direction of trauma, and arthroscopic repair may be possible.^{29,30} Recurrent torsional maneuvers subject the anterior portion of the articular-labral junction to recurrent microtrauma and tears.³⁴ Pivoting or twisting sports activity appears to create a predisposition to these injury patterns.

The clinical examination of patients with a labral tear has historically been difficult. Some studies failed to find a direct correlation between specific maneuvers and labral injuries.³⁵ However, a positive Thomas test (in which bilateral hip flexion is followed by abduction and extension of the involved hip, producing pain and a palpable or audible click), was found to be correlated with surgical pathology.³⁶ In the proposed McCarthy test, both hips are flexed, while the affected

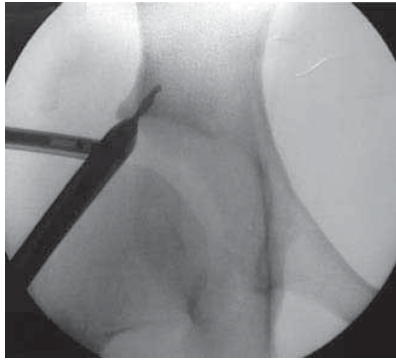


Figure 4 A fluoroscopic image confirming the position of the drill before anchor insertion. It is critical to ensure that the drill diverges from the joint.

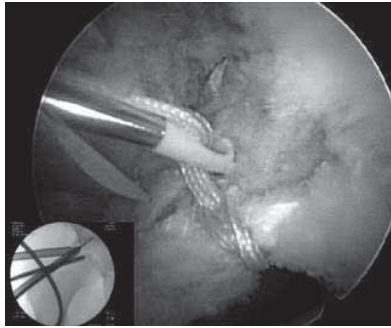


Figure 5 An endoscopic view of the suture anchor in place after labral repair in the right hip, taken from the anterolateral portal. The femoral head is located to the right of the image. A fluoroscopic image of drill placement is shown (inset).

hip is extended first in external rotation and then in internal rotation. Hip extension in internal rotation causes stress on the anterior labrum, and extension with external rotation elicits posterior symptoms.³⁰ The anterior and posterior impingement tests also are commonly used to evaluate for anterolateral and posterolateral rim pathology.

Although radiographic findings are often unremarkable, specific attention should be given to the anterolateral and superior femoral head-neck junction and the acetabulum for evidence of FAI.³ Contrast-enhanced magnetic resonance arthrography has been shown to be more sensitive than standard MRI for detecting intra-articular lesions of the hip.^{33,37}

The decision to proceed with surgical intervention should be based on refractory pain or mechanical symptoms. Although most labral tears are treated by débridement, some can be repaired arthroscopically. Peterson and associates³⁸ studied the blood supply to the labrum and found that blood vessels enter the labrum from the adjacent joint capsule. Vascularity was detected

only in the peripheral one third of the labrum; the inner two thirds of the labrum were avascular. Thus, peripheral tears, which are relatively uncommon, appear to have healing potential, and repair should be considered. McCarthy and associates reported on 436 consecutive hip arthroscopies, of which 261 revealed labral tears. All of the labral tears were located at the articular junction and were not considered ideal for repair.^{29,30} Many of these articular-side detachments may have had a deep extension to, but not through, the vascular periphery of the labrum. Creating a bleeding bony bed beneath the tear may be analogous to creating a red-white healing zone to promote labral healing.

Routine anterior and anterolateral portals can be used in arthroscopic labral repair, as well as an accessory midanterior portal located halfway between the anterior and anterolateral portals and about 2 cm distal to them.³⁹ Alternatively, the anterior portal may be 1 to 2 cm inferior to the usual location to allow an appropriate angle for anchor placement. To prepare for the repair, a standard débridement is per-

formed, similar to that used in the shoulder. Sometimes the periphery of the labrum can be detached through the area of undersurface tearing, allowing acetabular rim preparation and ease of anchor placement. Anchor positioning to avoid chondral injury is critical with respect to the femoral head (when the anchor is delivered) and acetabular penetration. Endoscopic and fluoroscopic evaluation can confirm appropriate anchor placement (Figure 4). The options for repair include the use of traditional suture anchors with arthroscopic knot tying, and, more recently, the use of knotless anchors (Figure 5).

Good short-term outcomes have been reported after arthroscopic labral repair.^{40,41} Longer-term studies are available only for open techniques, and they support the value of labral repair.² When indicated, labral repair should be considered to alleviate symptoms and prevent or delay the development of degenerative changes.

Snapping Hip

A benign, painless snapping hip (coxa saltans) is common among athletes. Symptomatic snapping with debilitating pain often occurs in dancers, gymnasts, and runners. The cause of the snapping can be internal or external. Several intra-articular conditions, including labral tears, loose bodies, and synovial chondromatosis, may be experienced as hip snapping.⁴²⁻⁴⁴

The iliotibial band is under tension throughout the hip's range of motion and is the most common external source of hip snapping. It lies posterior to the greater trochanter as the hip is extended and moves anteriorly with flexion. In some patients, a thickened posterior portion of the iliotibial band can snap over the

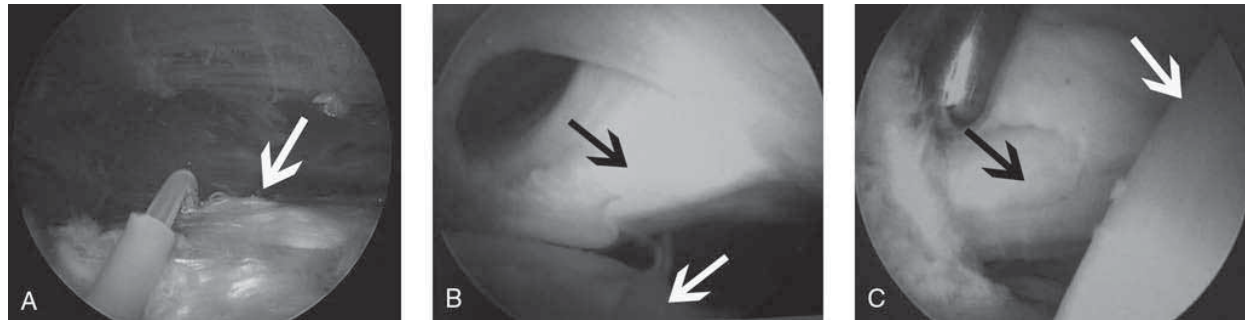


Figure 6 **A**, The iliopsoas tendon (*arrow*) seen from the lesser trochanteric bursa before release with electrocautery. **B**, The iliopsoas tendon (*black arrow*) seen from the peripheral compartment. The femoral head can be seen below the tendon (*white arrow*). **C**, A shaver is used from the central compartment, with traction, to remove the capsule and expose the iliopsoas tendon (*black arrow*). With the camera in the anterolateral portal, the shaver was introduced through the anterior portal. The acetabulum and the labrum are to the left, and the femoral head is to the right (*white arrow*).

greater trochanter. The anterior aspect of the gluteus maximus can also create external snapping as it rubs over the greater trochanter. The greater trochanteric bursa can become inflamed and painful as a result of this mechanical irritation, causing disability.⁴²

The iliopsoas (a confluence of the iliacus and the psoas muscles) is the most common internal source of snapping. Internal snapping can result from an anteromedial bony prominence adjacent to the lesser trochanter, over which the tendinous portion of the muscle passes before its insertion. Other reported mechanisms include the iliopectineal eminence, a prominent head-neck junction, or a prominent acetabular rim, which can be associated with FAI. Internal snapping associated with pincer impingement and a labral tear has been called triple impingement. The iliopsoas bursa also can become inflamed and lead to painful snapping.^{42,45} With flexion, abduction, and external rotation, the tendinous portion of the iliopsoas lies lateral to the anterior aspect of the femoral head. Snapping results when the iliopsoas moves into a more medial position with ex-

tension, adduction, and internal rotation.

The patient's description of the location of the snapping is key to determining its source. Internal snapping is felt deep in the groin or anterior hip, and external snapping is felt over the greater trochanter. Some patients report feeling instability or a dislocating hip as a result of the mechanical snap. Clinical examination usually is straightforward, and external snapping is obvious. Internal snapping is best evaluated with the patient supine. The diagnosis is confirmed by pressure applied over the tendon at the inferior margin of the inguinal ligament, which should obliterate the snapping.⁴⁶

Imaging studies, including radiographs, are important to rule out significant bony involvement, such as FAI or a bony prominence at the lesser trochanter, although only dynamic ultrasonography is usually revealing. Bursography or tenography may be necessary to establish the diagnosis.^{47,48}

Most snapping, whether internal or external, is benign. Stretching exercises, physical therapy, and judicious use of corticosteroids have been shown to be successful in

treating most patients.⁴⁹ If the symptoms are not resolved with therapy and injections, surgical intervention is indicated. Internal snapping procedures release or fractionally lengthen the iliopsoas tendon to decrease the snapping and pain. The procedure was found to be successful using an open or arthroscopic approach.^{50,51} Arthroscopic release can be performed through the lesser trochanteric bursa, the peripheral compartment, or the central compartment (Figure 6). The tendinous portion of the iliopsoas is released using an electrocautery device and leaving the overlying muscle belly intact. Symptomatic heterotopic bone may form after surgery, although a postsurgical course of anti-inflammatory drugs can reduce the risk.

The treatment of external snapping involves releasing or lengthening the iliotibial band, or both, using an open or arthroscopic approach.^{49,52} The endoscopic technique is most commonly used with the patient in the lateral position, although it can be performed with the patient supine to accommodate a concomitant hip arthroscopy procedure.⁵² With the patient in the later-

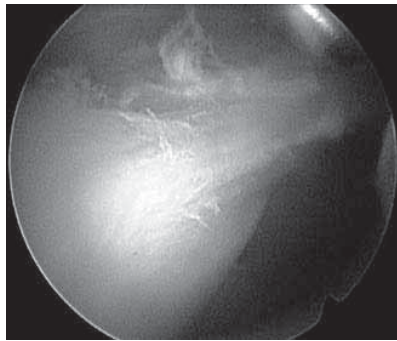


Figure 7 The position of the superior and inferior trochanteric portals for endoscopic iliotibial band release. The portals are approximately 2 cm proximal to the prominence of the greater trochanter and 2 cm distal to the inferior prominence of the trochanter.

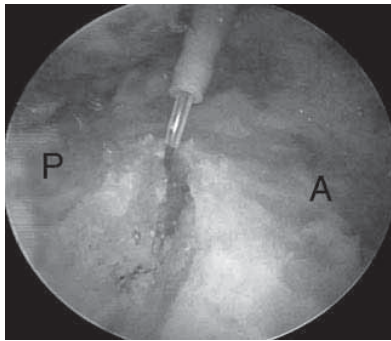


Figure 8 A longitudinal incision in the iliotibial band of a right hip, as seen from the distal portal. A = anterior, P = posterior.

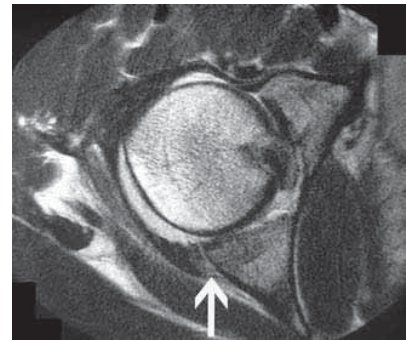


Figure 9 An axial T1-weighted MRI scan showing posterior hip subluxation and a nondisplaced posterior acetabular fracture (*arrow*), an anterior labral tear, and disruption of the iliofemoral ligament with a hemarthrosis.

al position, superior and inferior trochanteric portals are established (Figure 7). The endoscopic procedure begins lateral to the iliotibial band with creation of a window directly over the trochanteric prominence using an electrocautery device (Figure 8). When the prominence of the trochanter is exposed, a bursectomy is performed to clear all reactive tissue and any bony prominences. The peritrochanteric space should be evaluated, and gluteus medius or minimus insertion disruptions should be treated.⁵³

Hip Instability

Hip instability can have a traumatic or atraumatic origin. The most common traumatic mechanism of hip dislocation is a motor vehicle crash in which the patient's knees hit the dashboard. During athletic activity, a forward fall onto a knee while the hip was flexed or a blow from behind while the athlete was down on all four limbs can also result in hip subluxation or dislocation.^{54,55} Atraumatic instability is more subtle and can be associated

with hypermobility of the hip joint caused by repetitive overuse or inherent capsular laxity resulting in rotational microinstability. This condition may be more severe in patients with generalized ligamentous laxity or, in the extreme form, with a connective tissue disorder such as Marfan syndrome or Ehlers-Danlos syndrome.^{43,56,57} Atraumatic instability also can be caused by osseous anatomic abnormality on either the acetabular or femoral side.^{57,58}

The diagnosis of a hip dislocation usually is clear. However, hip subluxation can be quite subtle and can occur after seemingly minimal trauma.⁵⁹⁻⁶² Atraumatic hip instability is even more difficult to diagnose. Because the differential diagnosis of hip pain is broad, taking an accurate patient history is critical. Any overuse activity with repetitive stress, such as figure skating, golf, football, baseball, martial arts, ballet, or gymnastics, can injure the iliofemoral ligament or labrum and alter the balance of forces in the hip. These abnormal forces increase tension and microinstability on the an-

terior joint capsule and can lead to capsular redundancy, labral injury and impingement, and neck impingement at high flexion angles.^{56,63} On physical examination, patients usually experience anterior hip pain in the prone position, with passive hip extension and external rotation. These forces can alter dynamic stabilizers such as the iliopsoas, leading to psoas and flexion contracture, internal coxa saltans,⁴³ and pain in the low back and sacroiliac joint.

For any diagnosis of instability, AP and lateral radiographs are required. Judet oblique radiographs are used to further evaluate the acetabulum for fractures, and fine-cut CT through the acetabulum also is typically required. MRI is critical in evaluating both traumatic and atraumatic instability. In traumatic posterior hip subluxation or dislocation, the classic MRI findings include a posterior acetabular lip fracture, iliofemoral ligament disruption, and hemarthrosis^{55,64} (Figure 9). MRI should be performed approximately 6 weeks after a traumatic hip injury

to detect osteonecrosis.^{55,65} MRI is useful in detecting subtle derangements in capsulolabral structures in a chronic atraumatic injury.⁶⁶⁻⁶⁸

The initial treatment of a hip dislocation focuses on urgent concentric reduction; the secondary phase focuses on definitive care.⁶⁹ The reported incidence of osteonecrosis after hip dislocation ranges from 1% to 17%.⁷⁰⁻⁷² Posttraumatic arthritis and persistent capsular laxity or instability can also occur.⁷³⁻⁷⁸ The risk of osteonecrosis is diminished if closed reduction is performed within 6 hours of the initial injury.⁷⁰ A dislocation without associated fracture or with only a small acetabular rim fracture can be treated nonsurgically. Surgical treatment is warranted if significant osseous injuries or incarcerated bony fragments are present or if the initial reduction was nonconcentric. Surgical reconstruction of an associated acetabular injury is necessary only for a displaced fracture or a nondisplaced injury involving 20% to 40% of the weight-bearing zone of the acetabulum to allow early motion and ambulation with a stable and congruent joint.^{59,79}

Posterior hip subluxation must be promptly diagnosed using MRI. Immediate aspiration is recommended if a large effusion is detected,⁵⁵ and large cartilaginous loose bodies floating in the central and peripheral compartments may require arthroscopic removal. Hip arthroscopy can be used as an adjuvant to open surgery to treat femoral head pathology, chondral injuries, loose bodies, ligamentum teres injuries, and labral pathology.⁶⁴ Figure 10 outlines a general treatment algorithm for traumatic hip dislocations and subluxations.

Atraumatic instability is difficult to assess, define, and treat, and treat-

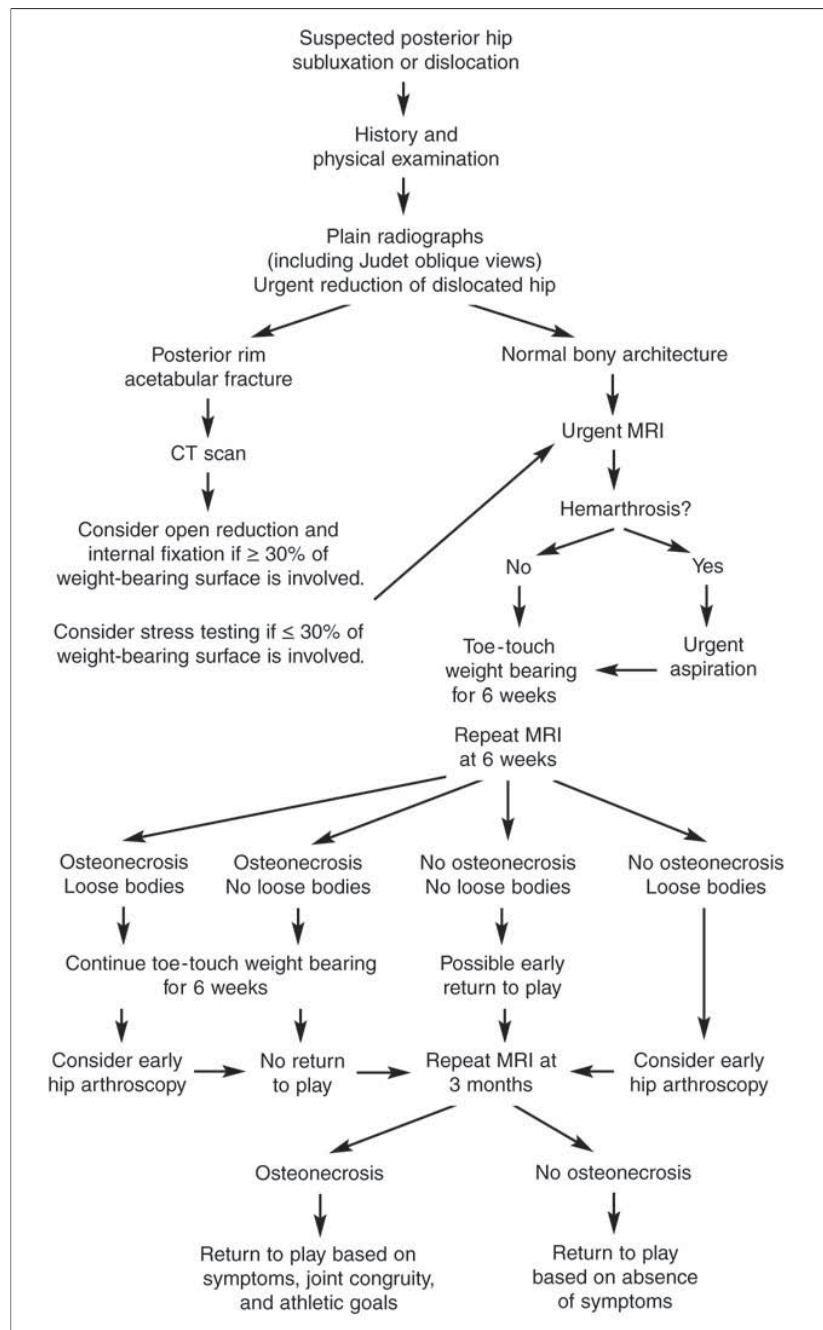


Figure 10 The treatment algorithm used for hip subluxation or dislocation in an athlete.

ment strategies are still developing.⁶⁴ As diagnostic and therapeutic capabilities improve, atraumatic instability increasingly is recognized as

a distinct entity. In a patient whose physical examination, history, and imaging studies are consistent with capsulolabral injury and instability,

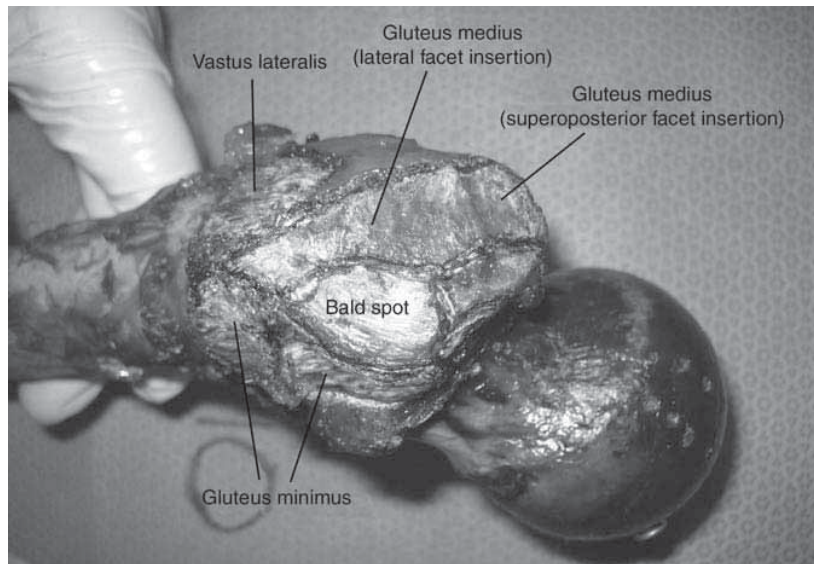


Figure 11 The two insertion sites of the gluteus medius. The thickest portion of the tendon inserts into the superoposterior facet of the greater trochanter in a circular footprint pattern, with a second, broad insertion on the lateral facet.

physical therapy and anti-inflammatory drugs may be used in an attempt to break the cycle of painful capsulolabral pathology. If this treatment is unsuccessful but an intra-articular anesthetic injection relieves the patient's pain, hip arthroscopy is considered. Anatomic labral repair and a reduction in capsular laxity using thermal capsulorrhaphy or capsular plication have had favorable preliminary results.^{34,56,64,77} If atraumatic instability is caused by poor osseous coverage, as in dysplasia, excessive femoral valgus, or increased femoral anteversion, hip arthroscopy should be used only with extreme caution, and redirection osteotomies should be considered.^{26,80}

Peritrochanteric Disorders

Lateral hip pain, also called greater trochanteric pain syndrome, is characterized by a chronic, intermittent aching pain over the lateral aspect of the hip. The pain is caused by bursal

inflammation in the peritrochanteric space from either extra-articular or intra-articular derangements.⁸¹ Possible intra-articular causes must be evaluated first. The common extra-articular causes include occult abductor pathology (tears of the gluteus medius or minimus) and an external snapping hip (coxa saltans).⁴² Greater trochanteric pain syndrome is traditionally described as inflammation of the trochanteric bursa that predominantly lies over the posterior facet of the trochanter. The evidence increasingly suggests that persistent pain and weakness in this region results from primary deficiencies in the tendon attachments of the gluteus medius or minimus.⁸²⁻⁸⁴ Like rotator cuff tears, these abductor tears can be either traumatic or degenerative and are commonly found in older female patients.^{85,86}

The peritrochanteric space is the region between the greater trochanter and the iliotibial band. It is

comparable to the subacromial space in the shoulder. The greater trochanter has four distinct facets (anterior, lateral, superoposterior, and posterior), three of which have independent tendon insertions.⁸⁷ The gluteus medius has two distinct insertion sites. The thickest portion of the tendon inserts onto the superoposterior facet in a circular footprint pattern, and a second, broad-based insertion is on the lateral facet (Figure 11). The gluteus minimus inserts primarily on the anterior facet deep to the medius and functions as a stabilizing force to the hip joint.⁸⁸ A bald spot lies between the insertion sites of the gluteus minimus and the lateral facet of the gluteus medius. The greater trochanteric bursa overlies the posterior facet, which is devoid of any discrete tendon insertion.

Direct manual palpation is critical in determining the etiology of lateral hip pain. Usually intra-articular referred pain is not elicited by palpation but by joint motion, and peritrochanteric disorders are painful with manual pressure. A proper evaluation of the peritrochanteric space begins with palpation of the gluteus maximus and the specific abductor insertions. Manual muscle strength testing should be performed with the hip in flexion, neutral, and extension to assess the tensor fascia lata, gluteus medius, and gluteus maximus, respectively. Strength testing should be performed with the knee in extension, when the iliotibial band contributes to strength, and in flexion, when the iliotibial band does not contribute. Abductor contractures can be assessed using the Ober test, which also should be performed with the hip in flexion, neutral, and extension. The classic Ober test is performed in extension to evaluate ten-

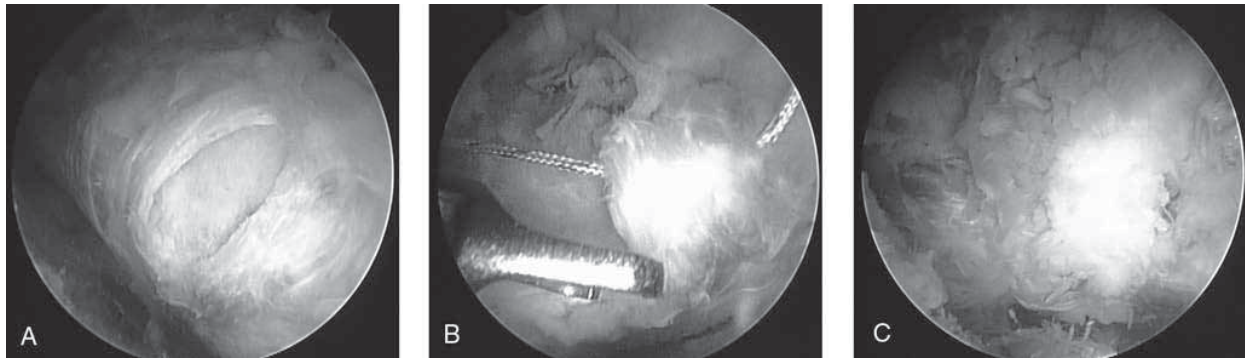


Figure 12 Arthroscopic repair of a focal tear of the gluteus medius tendon using a Corkscrew suture anchor (Arthex, Naples, FL). **A**, The pattern of the full-thickness tear of the gluteus medius tendon. **B**, Placement of two anchors. **C**, The final repair, after arthroscopic knots are tied.

sion across the tensor fascia lata.⁸⁹

The imaging studies for diagnosing recalcitrant lateral hip pain are similar to those used for atraumatic instability. Plain radiography is initially used. MRI is necessary for a patient with a presumed diagnosis of trochanteric bursitis or abductor dysfunction who has not responded to nonsurgical treatment.⁶³ MRI may reveal a previously unappreciated tear of the gluteus medius, which has been well described in the literature as a possible cause of greater trochanteric pain syndrome.⁸²⁻⁸⁴ In a patient with a snapping hip (coxa saltans), dynamic ultrasonography can confirm the diagnosis.⁹⁰

Physical therapy and judicious corticosteroid and local anesthetic injections are the mainstays for diagnosing and treating trochanteric bursitis.⁹¹ Numerous surgical procedures have been described for use after unsuccessful nonsurgical treatment.^{49,92} Arthroscopic treatment of extra-articular lateral hip pathology has recently been described for recalcitrant trochanteric bursitis; as many as 85% of patients had a good or excellent result after 1 to 5 years.^{91,93,94}

Trochanteric bursitis that is re-

fractory after multiple corticosteroid injections often reflects an undiagnosed tear of the gluteus medius or minimus tendon. Tears of the gluteus medius and minimus encountered during open surgery for refractory trochanteric bursitis were described as rotator cuff tears of the hip.^{84,95,96} Like the rotator cuff, the abductors can develop calcific tendinitis.^{97,98} Although the incidence of symptomatic abductor tears is not well defined, abductor pathology has been identified in as many of 11% of patients with femoral neck fracture and 20% of patients after total hip arthroplasty.^{96,99} The use of MRI has improved the diagnosis of tears of the gluteus medius tendon.^{82,100} Open surgery has been the mainstay of treatment for tears of the gluteus medius and minimus tendons.^{85,86} Arthroscopic techniques have been described for excision of calcific tendinitis of the gluteus medius and minimus tendons,¹⁰¹ and an endoscopic repair with suture anchors has been described for focal tears of the gluteus medius and minimus tendons¹⁰² (Figure 12). External snapping hip or coxa saltans is another pathoanatomic entity in the peritro-

chanteric space.^{42,49,52,103,104}

Summary

Disorders of the hip joint are better understood as a result of arthroscopic and open procedures developed by specialists in sports medicine and reconstruction. Future cadaver and biomechanical studies and well-designed clinical outcomes research will further define the indications for open and arthroscopic procedures of the hip.

References

1. Beck M, Leunig M, Parvizi J, et al: Anterior femoroacetabular impingement: Part II. Midterm results of surgical treatment. *Clin Orthop Relat Res* 2004;418:67-73.
2. Espinosa N, Rothenfluh DA, Beck M, et al: Treatment of femoroacetabular impingement: Preliminary results of labral refixation. *J Bone Joint Surg Am* 2006;88:925-935.
3. Ganz R, Parvizi J, Beck M, et al: Femoroacetabular impingement: A cause for osteoarthritis of the hip. *Clin Orthop Relat Res* 2003;417:112-120.
4. Philippon MJ, Schenker ML: Arthroscopy for the treatment of femoroacetabular impingement in the ath-

- lete. *Clin Sports Med* 2006;25:299-308.
5. Leunig M, Beck M, Dora C, et al: Femoroacetabular impingement: Etiology and surgical concept. *Oper Tech Orthop* 2005;15:247-255.
 6. Siebenrock KA, Kalbermatten DF, Ganz R: Effect of pelvic tilt on acetabular retroversion: A study of pelvises from cadavers. *Clin Orthop Relat Res* 2003;407:241-248.
 7. Reynolds D, Lucas J, Klaue K: Retroversion of the acetabulum: A cause of hip pain. *J Bone Joint Surg Br* 1999;81:281-288.
 8. Ruelle M, Dubois JL: The protrusive malformation and its arthritic complication: 1. Radiologic and clinical symptoms: Enteropathogenesis. *Rev Rheum Mal Osteoartic* 1962;29:476-489.
 9. Murphy S, Tannast M, Kim YJ, et al: Debridement of the adult hip for femoroacetabular impingement. *Clin Orthop Relat Res* 2004;429:178-181.
 10. Peters CL, Erickson JA: Treatment of femoro-acetabular impingement with surgical dislocation and debridement in young adults. *J Bone Joint Surg Am* 2006;88:1735-1741.
 11. Sampson TG: Arthroscopic treatment of femoroacetabular impingement: A proposed technique with clinical experience. *Instr Course Lect* 2006;55:337-346.
 12. Guanche CA, Bare AA: Arthroscopic treatment of femoro-acetabular impingement. *Arthroscopy* 2006;22:95-106.
 13. Philippon MJ, Schenker ML, Briggs KK, Kuppessmith DA, Maxwell RB, Stubbs AJ: Revision hip arthroscopy. *Am J Sports Med* 2007;35:1918-1921.
 14. Philippon M, Schenker M, Briggs K, Kuppessmith D: Femoroacetabular impingement in 45 professional athletes: Associated pathologies and return to sport following arthroscopic decompression. *Knee Surg Sports Traumatol Arthrosc* 2007;15:908-914.
 15. Philippon MJ, Schenker ML: A new method for acetabular rim trimming and labral repair. *Clin Sports Med* 2006;25:293-297.
 16. Sampson TG: Arthroscopic treatment of femoroacetabular impingement: A proposed technique with clinical experience. *Instr Course Lect* 2006;55:337-346.
 17. Wettstein M, Dienst M: Hip arthroscopy for femoroacetabular impingement. *Orthopade* 2006;35:85-93.
 18. Philippon MJ, Stubbs AJ, Schenker ML, Maxwell RB, Ganz R, Leunig M: Arthroscopic management of femoroacetabular impingement: Osteoplasty technique and literature review. *Am J Sports Med* 2007;35:1571-1580.
 19. Larson CM, Giveans R: Arthroscopic management of femoro-acetabular impingement: Early outcomes measures. *Arthroscopy* 2008;24(5).
 20. Clohisy JC, McClure JT: Treatment of anterior femoroacetabular impingement with combined hip arthroscopy and limited anterior decompression. *Iowa Orthop J* 2005;25:164-171.
 21. Zebala LP, Clohisy JC: Combined hip arthroscopy and limited open osteochondroplasty for treating impingement disease. *74th Annual Meeting Proceedings*. Rosemont, IL, American Academy of Orthopaedic Surgeons, 2007, p 379.
 22. Gautier E, Ganz K, Krugel N, Gill T, Ganz R: Anatomy of the medial femoral circumflex artery and its surgical implications. *J Bone Joint Surg Br* 2000;82:679-683.
 23. Mardones RM, Gonzalez C, Chen Q, Zobitz M, Kaufman KR, Trousdale RT: Surgical treatment of femoroacetabular impingement: Evaluation of the effect of the size of the resection. *J Bone Joint Surg Am* 2005;87:273-279.
 24. Burnett RS, Della Rocca GJ, Prather H, Curry M, Maloney WJ, Clohisy JC: Clinical presentation of patients with tears of the acetabular labrum. *J Bone Joint Surg Am* 2006;88:1448-1457.
 25. Klaue K, Durnin CW, Ganz R: The acetabular rim syndrome: A clinical presentation of dysplasia of the hip. *J Bone Joint Surg Br* 1991;73:423-429.
 26. Ganz R, Klaue K, Vinh TS, Mast JW: A new periacetabular osteotomy for the treatment of hip dysplasias: Technique and preliminary results. *Clin Orthop Relat Res* 1988;232:26-36.
 27. Ferguson SJ, Bryant JT, Ganz et al: An in vitro investigation of the acetabular labral seal in hip joint mechanics. *J Biomech* 2003;36:171-178.
 28. Kim YT, Azuma H: The nerve endings of the acetabular labrum. *Clin Orthop Relat Res* 1995;320:176-181.
 29. McCarthy J, Barsoum W, Puri L, Lee J, Murphy S, Cooke P: The role of hip arthroscopy in the elite athlete. *Clin Orthop Relat Res* 2003;406:71-74.
 30. McCarthy J, Noble P, Aluisio FV, Schuck M, Wright J, Lee JA: Anatomy, pathologic features, and treatment of acetabular labral tears. *Clin Orthop Relat Res* 2003;406:38-47.
 31. Mason JB: Acetabular labral tears in the athlete. *Clin Sports Med* 2001;20:779-790.
 32. Lage LA, Patel JV, Villar RN: The acetabular labral tear: An arthroscopic classification. *Arthroscopy* 1996;12:269-272.
 33. Neumann G, Mendicuti AD, Zou KH, et al: Prevalence of labral tears and cartilage loss in patients with mechanical symptoms of the hip: Evaluation using MR arthrography. *Osteoarthritis Cartilage* 2007;15:909-917.
 34. Philippon MJ: Debridement of acetabular labral tears associated with thermal capsulorrhaphy. *Oper Tech Sports Med* 2002;10:215-218.
 35. Farjo LA, Glick JM, Sampson TG: Hip arthroscopy for acetabular labral tears. *Arthroscopy* 1999;15:132-137.
 36. Fitzgerald RH Jr: Acetabular labral tears: Diagnosis and treatment. *Clin Orthop Relat Res* 1995;311:60-68.
 37. Czerny C, Hofmann S, Urban M, et al: MR arthrography of the adult acetabular capsular-labral complex: Correlation with surgery and

- anatomy. *AJR Am J Roentgenol* 1999; 173:345-349.
38. Petersen W, Petersen F, Tillman B: Structure and vascularization of the acetabular labrum with regard to the pathogenesis and healing of labral lesions. *Arch Orthop Trauma Surg* 2003; 123:282-288.
 39. Byrd JW: Hip arthroscopy utilizing the supine position. *Arthroscopy* 1994; 10:275-280.
 40. Hines SL, Philippon MJ, Kupper-Smith D, et al: Early results of labral repair. *Arthroscopy* 2007;23:e9-e10.
 41. Ross AE, Javernick M, Freedman B, et al: Arthroscopic hip labral repair. *Arthroscopy* 2006;22:e30.
 42. Allen WC, Cope R: Coxa saltans: The snapping hip revisited. *J Am Acad Orthop Surg* 1995;3:303-308.
 43. Bellabarba C, Sheinkop MB, Kuo KN: Idiopathic hip instability: An unrecognized cause of coxa saltans in the adult. *Clin Orthop Relat Res* 1998;355: 261-271.
 44. Ikeda T, Awaya G, Suzuki S, et al: Torn acetabular labrum in young patients: Arthroscopic diagnosis and management. *J Bone Joint Surg Br* 1988;70:13-16.
 45. Schaberg JE, Harper MC, Allen WC: The snapping hip syndrome. *Am J Sports Med* 1984;12:361-365.
 46. Larsen E, Johansen J: Snapping hip. *Acta Orthop Scand* 1986;57:168-170.
 47. Cardinal E, Buckwalter KA, Capello WN, et al: US of the snapping iliopsoas tendon. *Radiology* 1996;198: 521-522.
 48. Pelsser V, Cardinal E, Hobden R, et al: Extraarticular snapping hip: Sonographic findings. *AJR Am J Roentgenol* 2001;176:67-73.
 49. Zoltan DJ, Clancy WG Jr, Keene JS: A new operative approach to snapping hip and refractory trochanteric bursitis in athletes. *Am J Sports Med* 1986; 14:201-204.
 50. Flanum ME, Keene JS, Blankenbaker DG, et al: Arthroscopic treatment of the painful "internal" snapping hip: Results of a new endoscopic technique and imaging protocol. *Am J Sports Med* 2007;35:770-779.
 51. Jacobson T, Allen WC: Surgical correction of the snapping iliopsoas tendon. *Am J Sports Med* 1990;18: 470-474.
 52. Ilizaliturri VM, Martinez-Escalante FA, Chaidez PA, et al: Endoscopic iliotibial band release for external snapping hip syndrome. *Arthroscopy* 2006; 22:505-510.
 53. Voos JE, Rudzki JR, Shindle MC, et al: Arthroscopic anatomy and surgical techniques for peritrochanteric space disorders in the hip. *Arthroscopy* 2007; 23:1246.e1-5.
 54. Chudik S, Lopez V: Hip dislocations in athletes. *Sports Med Arthroscopy Review* 2002;10:123-133.
 55. Moorman CT III, Warren RF, Hershman EB, et al: Traumatic posterior hip subluxation in American football. *J Bone Joint Surg Am* 2003;85-A: 1190-1196.
 56. Philippon MJ: The role of arthroscopic thermal capsulorrhaphy in the hip. *Clin Sports Med* 2001;20:817-829.
 57. Tonnis D, Heinecke A: Acetabular and femoral anteversion: Relationship with osteoarthritis of the hip. *J Bone Joint Surg Am* 1999;81: 1747-1770.
 58. McKibbin B: Anatomical factors in the stability of the hip joint in the newborn. *J Bone Joint Surg Br* 1970;52: 148-159.
 59. Giza E, Mithofer K, Matthews H, Vrahas M: Hip fracture-dislocation in football: A report of two cases and review of the literature. *Br J Sports Med* 2004;38:e17.
 60. Lamke LO: Traumatic dislocations of the hip: Follow-up on cases from the Stockholm area. *Acta Orthop Scand* 1970;41:188-198.
 61. Mitchell JC, Giannoudis PV, Millner PA, Smith RM: A rare fracture-dislocation of the hip in a gymnast and review of the literature. *Br J Sports Med* 1999;33:283-284.
 62. Stiris MG: Magnetic resonance arthrography of the hip joint in patients with suspected rupture of labrum acetabulare. *Tidsskr Nor Laegeforen* 2001; 121:698-700.
 63. Kelly BT, Williams RJ III, Philippon MJ: Hip arthroscopy: Current indications, treatment options, and management issues. *Am J Sports Med* 2003;31: 1020-1037.
 64. Shindle MK, Ranawat AS, Kelly BT: Diagnosis and management of traumatic and atraumatic hip instability in the athletic patient. *Clin Sports Med* 2006;25:309-326.
 65. Poggi JJ, Callaghan JJ, Spritzer CE, Roark T, Goldner RD: Changes on magnetic resonance images after traumatic hip dislocation. *Clin Orthop Relat Res* 1995;319:249-259.
 66. Czerny C, Kramer J, Neuhold A: Magnetic resonance imaging and magnetic resonance arthrography of the acetabular labrum: Comparison with surgical findings. *Rofo Fortschr Geb Rontgenstr Neuen Bildgeb Verfahr* 2001;173:702-707.
 67. Byrd JW, Jones KS: Diagnostic accuracy of clinical assessment, magnetic resonance imaging, magnetic resonance arthrography, and intra-articular injection in hip arthroscopy patients. *Am J Sports Med* 2004;32: 1668-1674.
 68. Mintz DN, Hooper T, Connell D, Buly R, Padgett DE, Potter HG: Magnetic resonance imaging of the hip: Detection of labral and chondral abnormalities using noncontrast imaging. *Arthroscopy* 2005;21:385-393.
 69. Yang EC, Cornwall R: Initial treatment of traumatic hip dislocations in the adult. *Clin Orthop Relat Res* 2000; 377:24-31.
 70. Paus B: Traumatic dislocations of the hip: Late results in 76 cases. *Acta Orthop Scand* 1951;21:99-112.
 71. Proctor H: Dislocations of the hip joint (excluding "central" dislocations) and their complications. *Injury* 1973;5:1-12.
 72. Rodriguez-Merchan EC: Osteonecrosis of the femoral head after traumatic hip dislocation in the adult. *Clin Orthop Relat Res* 2000;377:68-77.

73. Dall D, Macnab I, Gross A: Recurrent anterior dislocation of the hip. *J Bone Joint Surg Am* 1970;52:574-576.
74. Dameron TB: Bucket-handle tear of acetabular labrum accompanying posterior dislocation of the hip. *J Bone Joint Surg Am* 1959;41:131-134.
75. Nelson CL: Traumatic recurrent dislocation of the hip: Report of a case. *J Bone Joint Surg Am* 1970;52:128-130.
76. Liebenberg F, Dommissie GF: Recurrent post-traumatic dislocation of the hip. *J Bone Joint Surg Br* 1969;51:632-637.
77. Lieberman JR, Altchek DW, Salvati EA: Recurrent dislocation of a hip with a labral lesion: Treatment with a modified Bankart-type repair. Case report. *J Bone Joint Surg Am* 1993;75:1524-1527.
78. Rashleigh-Belcher HJ, Cannon SR: Recurrent dislocation of the hip with a "Bankart-type" lesion. *J Bone Joint Surg Br* 1986;68:398-399.
79. Matta J: Surgical treatment of acetabular fractures, in Levine A (ed): *Skeletal Trauma*. Philadelphia, PA, Saunders, 2003, pp 1109-1150.
80. Wenger DR, Bomar JD: Human hip dysplasia: Evolution of current treatment concepts. *J Orthop Sci* 2003;8:264-271.
81. Tortolani PJ, Carbone JJ, Quartararo LG: Greater trochanteric pain syndrome in patients referred to orthopedic spine specialists. *Spine J* 2002;2:251-254.
82. LaBan MM, Weir SK, Taylor RS: "Bald trochanter" spontaneous rupture of the conjoined tendons of the gluteus medius and minimus presenting as a trochanteric bursitis. *Am J Phys Med Rehabil* 2004;83:806-809.
83. Bird PA, Oakley SP, Shnier R, Kirkham BW: Prospective evaluation of magnetic resonance imaging and physical examination findings in patients with greater trochanteric pain syndrome. *Arthritis Rheum* 2001;44:2138-2145.
84. Kingzett-Taylor A, Tirman PF, Feller J, et al: Tendinosis and tears of gluteus medius and minimus muscles as a cause of hip pain: MR imaging findings. *AJR Am J Roentgenol* 1999;173:1123-1126.
85. Fisher DA, Almand JD, Watts MR: Operative repair of bilateral spontaneous gluteus medius and minimus tendon ruptures. *J Bone Joint Surg Am* 2007;89:1103-1107.
86. Lonner JH, Van Kleunen JP: Spontaneous rupture of the gluteus medius and minimus tendons. *Am J Orthop* 2002;31:579-581.
87. Dwek J, Pfirrmann C, Stanley A, Pathria M, Chung CB: MR imaging of the hip abductors: Normal anatomy and commonly encountered pathology at the greater trochanter. *Magn Reson Imaging Clin N Am* 2005;13:691-704.
88. Beck M, Sledge JB, Gautier E, Dora CF, Ganz R: The anatomy and function of the gluteus minimus muscle. *J Bone Joint Surg Br* 2000;82:358-363.
89. Reider B: Hip, pelvis, and thigh, in *The Orthopaedic Physical Examination*, ed 2. Philadelphia, PA, Saunders, 2004, p 192.
90. Choi YS, Lee SM, Song BY, Paik SH, Yoon YK: Dynamic sonography of external snapping hip syndrome. *J Ultrasound Med* 2002;21:753-758.
91. Fox JL: The role of arthroscopic bursectomy in the treatment of trochanteric bursitis. *Arthroscopy* 2002;18:E34.
92. Govaert LH, van der Vis HM, Marti RK, Albers GH: Trochanteric reduction osteotomy as a treatment for refractory trochanteric bursitis. *J Bone Joint Surg Br* 2003;85:199-203.
93. Wiese M, Rubenthaler F, Willburger RE, Fennes S, Haaker R: Early results of endoscopic trochanter bursectomy. *Int Orthop* 2004;28:218-221.
94. Baker CL Jr, Massie RV, Hurt WG, Savory CG: Arthroscopic bursectomy for recalcitrant trochanteric bursitis. *Arthroscopy* 2007;23:827-832.
95. Kagan A II: Rotator cuff tears of the hip. *Clin Orthop Relat Res* 1999;368:135-140.
96. Bunker TD, Esler CN, Leach WJ: Rotator-cuff tear of the hip. *J Bone Joint Surg Br* 1997;79:618-620.
97. Gordon EJ: Trochanteric bursitis and tendinitis. *Clin Orthop* 1961;20:193-202.
98. Leonard MH: Trochanteric syndrome: Calcareous and noncalcareous tendonitis and bursitis about the trochanter major. *J Am Med Assoc* 1958;168:175-177.
99. Howell GE, Biggs RE, Bourne RB: Prevalence of abductor mechanism tears of the hips in patients with osteoarthritis. *J Arthroplasty* 2001;16:121-123.
100. Cvitanic O, Henzie G, Skezas N, Lyons J, Minter J: MRI diagnosis of tears of the hip abductor tendons (gluteus medius and gluteus minimus). *AJR Am J Roentgenol* 2004;182:137-143.
101. Kandemir U, Bharam S, Philippon MJ, Fu FH: Endoscopic treatment of calcific tendinitis of gluteus medius and minimus. *Arthroscopy* 2003;19:E4.
102. Shindle MK, Voos JE, Heyworth BE, et al: Hip arthroscopy in the athletic patient: Current techniques and spectrum of disease. *J Bone Joint Surg Am* 2007;89(suppl 3):29-43.
103. White RA, Hughes MS, Burd T, Hamann J, Allen WC: A new operative approach in the correction of external coxa saltans: The snapping hip. *Am J Sports Med* 2004;32:1504-1508.
104. Farr D, Selesnick H, Janecki C, Cordas D: Arthroscopic bursectomy with concomitant iliotibial band release for the treatment of recalcitrant trochanteric bursitis. *Arthroscopy* 2007;23:905.e1-5.